

Jon R. Wagner, DDS

# A Clinical and Histological Case Study using Resorbable Hydroxylapatite for the Repair of Osseous Defects prior to Endosseous Implant Surgery

## Abstract

**A** clinical case—a follow-up clinical and histological study—is presented in this paper, which describes the use of resorbable hydroxylapatite **OSTEOGEN®** (HA Resorb)®, Implants Ltd., Holliswood, New York 11423 for the repair of a large mandibular lesion, followed by the placement of an endosseous dental implant six weeks after the graft placement. A comparison of the histological results of four-month and 14-month bone biopsies of resorbable hydroxylapatite grafts is included in this report.

## Introduction

The resorption of the alveolar process following tooth loss has always been a very serious problem for the restorative dentist and an enigma for the oral implantologist. Today, through the use of selected autogenous grafts, allografts, or resorbable alloplastic bone materials, specific defects of the residual bone or extraction sites can be materially improved in both shape and quality (Finn *et al.*, 1980; Judy, 1986a). These treated sites can now become eligible for endosseous implants. Even with the loss of cortical plates of bone, the socket or defect can be rebuilt with resorbable grafting materials. The osteoconductive materials effectively used are autogenous transplants, demineralized freeze-dried bone, or resorbable hydroxylapatite (Judy, 1986a,b).

For the past 3½ years, this author has used resorbable hydroxylapatite (OsteoGen®) exclusively for repairing most extraction sites, osseous defects, and sinus defects (augmentations), and in conjunction with all endosseous implant modalities inserted surgically. Resorbable and non-resorbable small-particle hydroxylapatite has been mixed for use in repairing periodontal defects around natural teeth as well (Hubbard, 1974;

LeGeros, 1988; Jarcho *et al.*, 1976; Linkow, 1984, 1986).

## Materials

OsteoGen® is a pure, uniquely resorbable hydroxylapatite (HA) implant material used for alloplastic augmentation and the repair of bone defects. The material is chemically and crystallographically equivalent to the mineral portion of human bone, specifically,  $\text{Ca}_{10}(\text{PO}_4)_6\text{OH}_2$  (Hubbard, 1974; LeGeros, 1988; Jarcho *et al.*, 1976; Linkow, 1986; Cranin *et al.*, 1987).

Density, crystal size, and porosity determine the resorbability of hydroxylapatite (HA) alloplastic implant materials. Densely sintered, pure hydroxylapatite ceramic has low microporosity, high density, and is prepared in relatively large particle size (18-40 mesh in most commercially available alloplastic preparations), by subjecting it to very slow resorption rates (LeGeros, 1988; Jarcho *et al.*, 1976). Conversely, resorbable hydroxylapatite (HA) is a highly micro-porous, non-sintered (non-ceramic) material composed of small particles measuring 300-400 microns (35-60 mesh), with a controlled, predictable rate of resorption. Sintered (non-resorbable) hydroxylapatite mate-

rials are often subject to fibrous encapsulation rather than becoming a viable part of the host bone (Linkow, 1984, 1986). On the other hand, as non-sintered (resorbable) hydroxylapatite resorbs, it acts as a mineral reservoir and induces new bone formation *via* osteoconductive mechanisms. This "mineral reservoir" concept has been demonstrated by numerous histological studies which strongly suggest a direct correlation between increasing bone density and maturation with an ongoing reduction in the mass of refractile crystalline particles of HA as a function of time.

The hemostatic microfibrillar collagen used with the resorbable hydroxylapatite is Avitene® (MedChem Products, Inc.). A one-to-four volume ratio of the microfibrillar collagen hemostat is mixed with the resorbable hydroxylapatite and freshly drawn venous blood. The mixture requires only a small amount of the microfibrillar collagen matrix for hemostasis to be produced. These materials are mixed in a sterile porcelain Petri dish to a thick putty-like consistency prior to placement. Although hydroxylapatite products are non-inflammatory and biocompatible, collagen products can cause allergic inflammatory reactions, and a patch test should be run prior to surgery, especially on patients who have numerous allergies (Judy, 1986a; Cranin *et al.*, 1987).

### Case History

A twenty-nine-year-old male presented with an acute lesion and cellulitis of the lower right side of his face and chin. A panoramic radiograph (Fig. 1) and an oral examination revealed a large periapical abscess about 1 cm in diameter in the region of the right mandibular lateral incisor and cuspid. Only six mandibular teeth remained, all in a very poor state, with gross dental caries and gingival inflammation. With the exception of his dental condition, nothing else was remarkable in the medical history.

An incision and drainage were performed, and antibiotic therapy was instituted. Lincocin™ 600 mg IM was given, followed by a ten-day regimen of oral Cleocin™, 250 mg t.i.d. Seven days later, with the acute infection dissipated, the patient was prepared, draped, and anesthetized in the usual manner, and the right lateral incisor and residual root of the cuspid were removed. The mucoperiosteum was reflected facially and lingually, and a large bony defect was revealed, with most of the facial cortical bone eroded at the extraction sites. A fenestration of the lingual cortical plate at the lateral incisor socket, approximately 6 mm in diameter, created a through-and-through bony defect at the level of the root apex. The area was curetted, decontaminated (Fig. 2), and filled with a mixture of re-

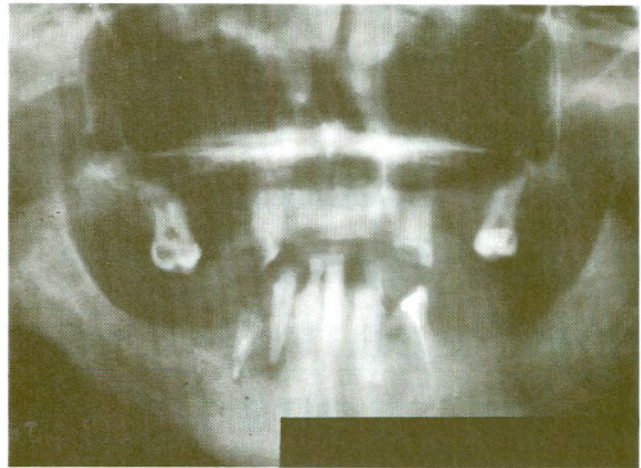


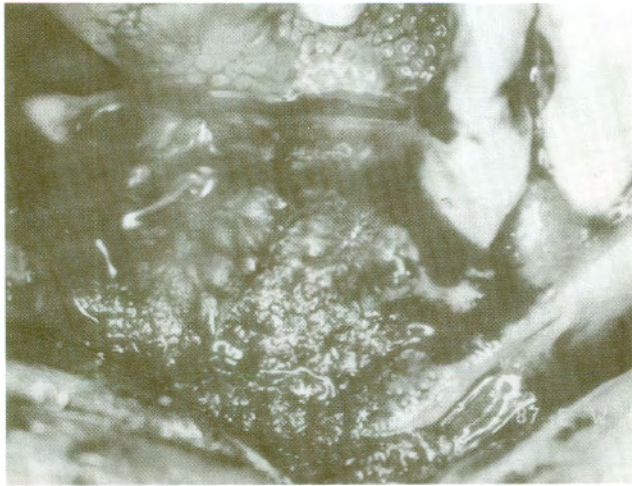
Figure 1. Pre-operative radiograph.

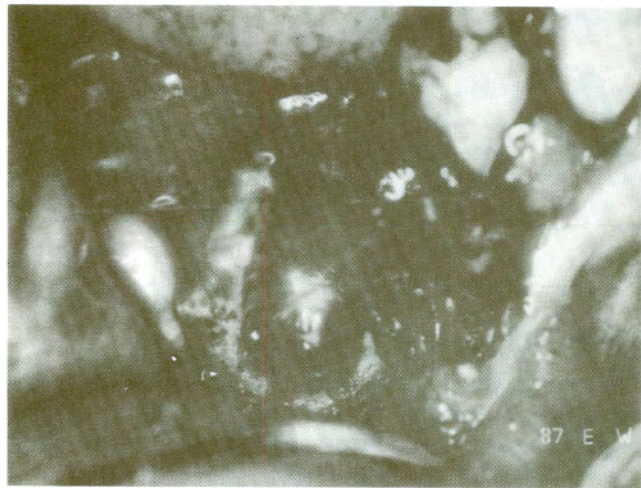

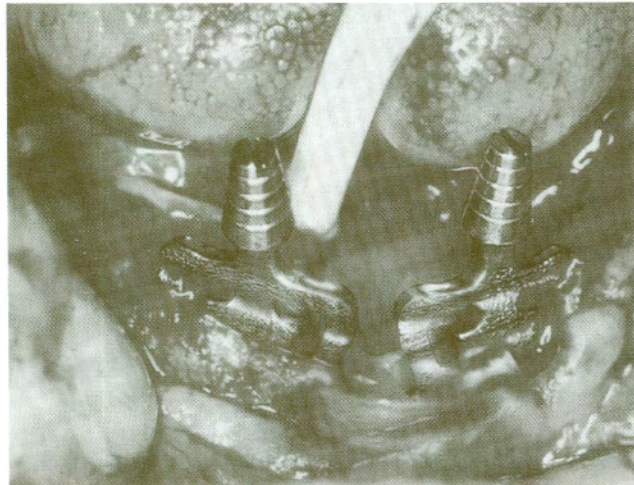
Figure 2. Mandibular right lateral and cuspid bone defect.

sorbable hydroxylapatite, a microfibrillar collagen matrix, and fresh venous blood. These materials were mixed with 125 mg of tetracycline powder to a thick putty-like consistency in a sterile porcelain Petri dish. The graft was packed into the sockets and bony defects and placed over the labial and crestal surfaces of the residual ridge, so that the ridge would be recontoured to its normal architecture (Fig. 3). The borders of the facial and lingual mucoperiosteal tissue flaps were trimmed of granulation and hypertrophic tissue to allow for coaptation and complete closure. Primary healing was uneventful.

Six weeks later, the remaining maxillary and mandibular teeth were extracted for the insertion of immediate dentures. Since the patient's job necessitated his leaving the area for several months after the extractions and dentures placement, it

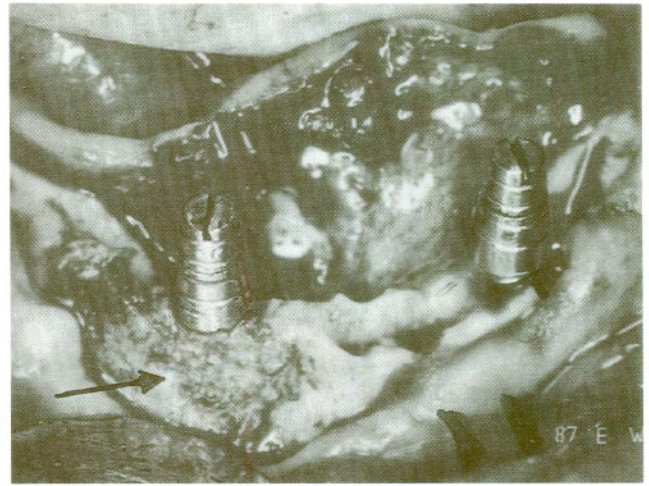


**Figure 3.** Resorbable hydroxylapatite graft immediately after placement.

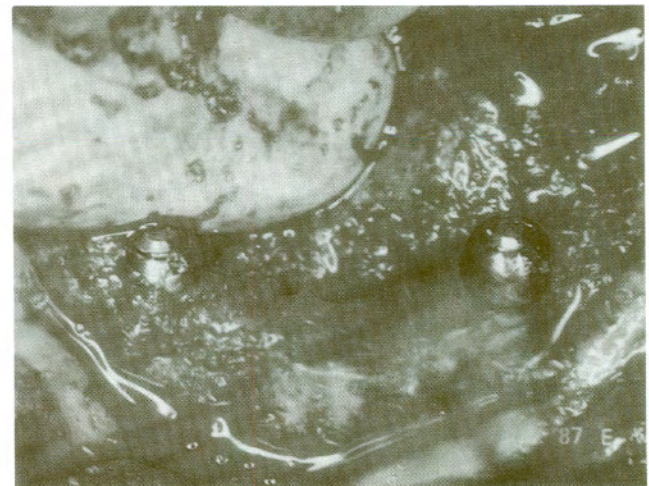

**Figure 4.** Titanium blade implants partially seated only six weeks after placement of the resorbable hydroxylapatite graft in the right cuspid and lateral incisor area.

was decided to insert two submersible titanium blade implants (Ultimatics, Inc., Springdale, AR) in the cuspid regions bilaterally and to allow these implants to heal without their prosthetic abutment posts during this interval. The grafted right canine and incisor areas were then surgically exposed and revealed a firm ridge that had maintained its architecture and dimensions with regenerating bone in an osteoid state. It was expected that the six-week-old resorbable hydroxylapatite graft would be fragile and easily displaced during the osteotomy or during the insertion of the right blade implant; however, the entire grafted labial plate remained intact. The graft was firm but still pliable and elastic, and tenaciously at-



**Figure 5.** Fully seated implants in osteotomy without displacement of six-week-old resorbable hydroxylapatite OsteoGen® graft (arrow).



**Figure 6.** Resorbable hydroxylapatite coagulum filling osteotomies and fresh extraction sites. Implants' abutment posts removed and healing collars in place.

tached to the bone substrate. After both osteotomies were completed, the two submersible blade implants were seated (Figs. 4, 5). The same resorbable hydroxylapatite coagulum was used to cover the shoulders of the implants, decorticated fresh extraction sites, and around the base of each healing cap (Figs. 6,7). Complete closure of soft tissue flaps allowed healing to occur in a non-functional and closed environment beneath the mucoperiosteal tissues.

Four months post-operatively, the patient was prepared, draped, and anesthetized. The mandibular ridge was surgically exposed from the right retro-molar pad to the left retro-molar pad, facially

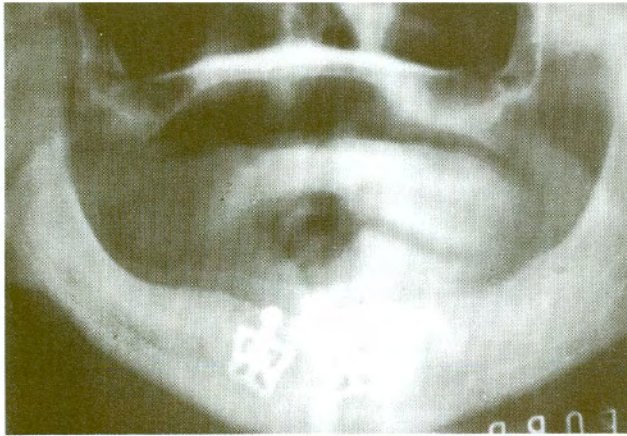


Figure 7. Panorex of submerged titanium implants and grafts.

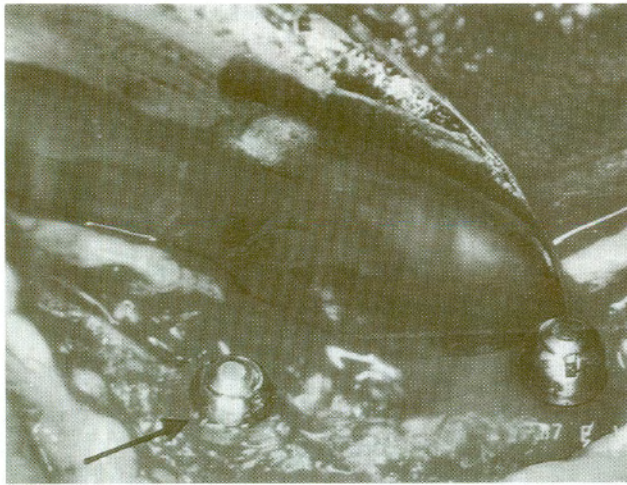


Figure 8. Site re-opened after four months, showing ossified grafts with bone up to and over the base of the implant healing collars.

and crestally. The two submerged implants in the canine region were completely covered to and over the bases of the healing caps, with newly regenerated bone (Fig. 8). The healing caps were removed, and the transepithelial prosthetic abutment posts were affixed to the implants. Two one-piece titanium double-abutment blade implants were surgically inserted into the posterior regions bilaterally, and the implants' shoulders and facial cortical plates were overlaid with the same mixture of resorbable hydroxylapatite, microfibrillar collagen, and fresh venous blood as was described in the first surgery. A bone core specimen was then harvested and fixed in 95% ethanol for analysis by means of a 5.5-mm trephine instrument and copious water irrigation at the previously grafted right cuspid apex area. The biopsy osteotomy was grafted

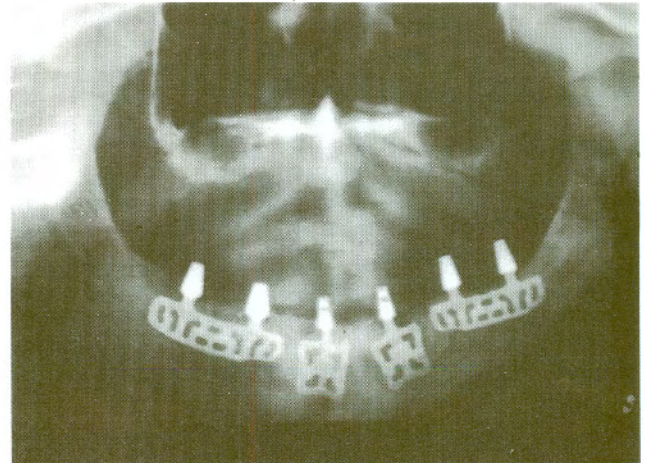


Figure 9. Post-op Panorex of seated implants with abutment heads and resorbable hydroxylapatite grafts.

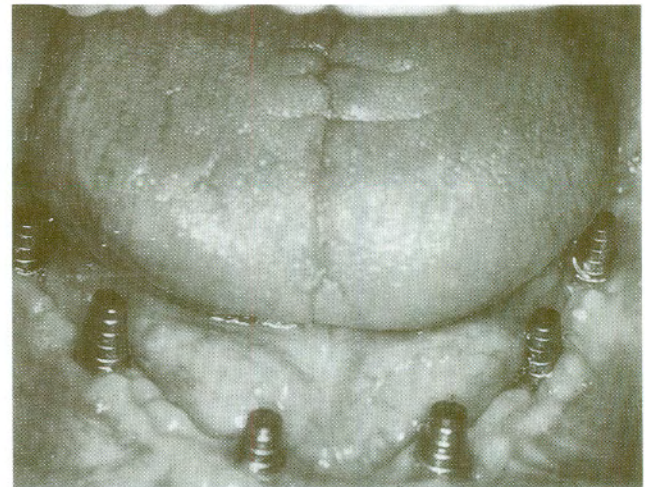


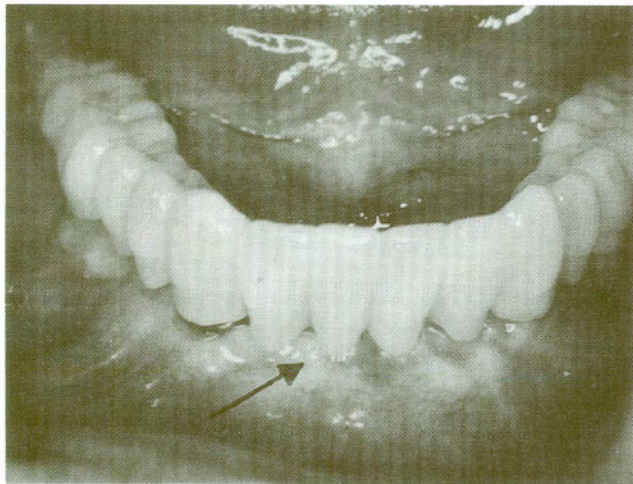
Figure 10. Three-week post-op of healing surgery.

with the resorbable hydroxylapatite coagulum (Fig. 9). Complete closure was performed by use of 3/0 chromic gut continuous and interrupted sutures. Healing was rapid and uneventful (Fig. 10). A full arch porcelain veneer bridge was constructed and subsequently cemented with hard cement (Fig. 11).

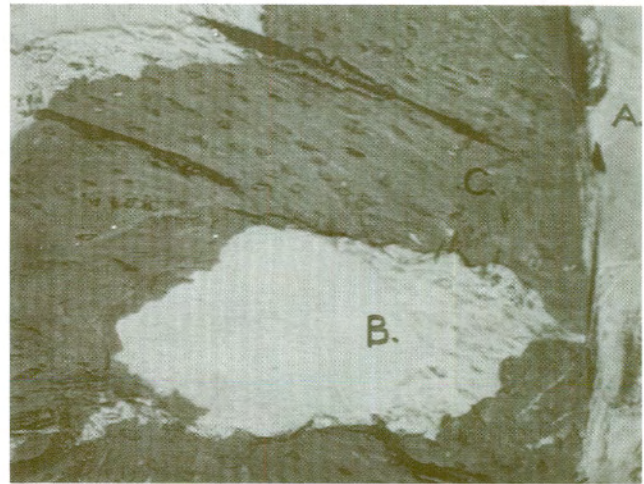
## Results

### Clinical

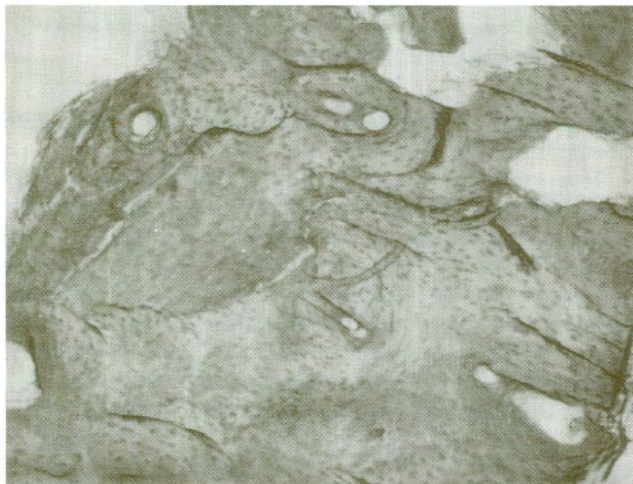After a year and a half, radiographic and clinical evaluation of the patient revealed excellent health of peri-implant tissue, with probing depths measuring between 0.5 and 0.75 mm. No signs of saucerization of crestal bone around the necks of the six abutment posts were discernible.



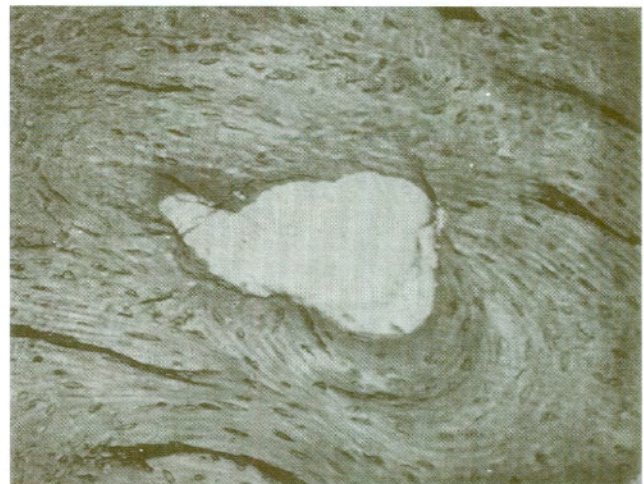**Figure 11.** Finished 14-unit porcelain veneer prosthesis. Note the length of anterior pontics. By retaining the architecture of the ridge through grafting procedures, it was possible for normal-length pontics to be maintained.



**Figure 13.** Resorbable hydroxylapatite crystal (B) with woven bone (C) showing a lack of inflammatory cells and in intimate contact with mature substrate bone (100 x).



**Figure 12.** Woven cancellous bone containing some refractile crystalline particles of resorbable hydroxylapatite bordered by substrate of mature natural bone (50 x).



**Figure 14.** Lamellated bone showing organization of newly formed bone in typical lamellar pattern (D) with an area of Haversian system formation (E) (100 x).

### **Histological**

A specimen with the HA graft (OsteoGen®) on the facial aspect of the right canine-lateral incisor area was sectioned without decalcification and stained with basic fuchsin.

---

*(Specimens were prepared by the George L. Schultz Laboratories for Orthopaedic Research, University of Medicine and Dentistry of New Jersey.)*

The slides demonstrate the formation of woven cancellous bone (Fig. 12), showing a lack of inflammatory cells and in intimate contact with mature substrate bone (Fig. 13). The interface of regenerating bone and host bone was deficient in the fibrous elements common with non-resorbable hydroxylapatite. Refractile crystals of the hydroxylapatite graft material were observed throughout the specimen. Sections taken near the surface of the specimen where the cortical plate was replaced show a typical lamellar pattern and Haversian system formation (Fig. 14). At higher magnification (200 X), the resorbable hydroxylapatite (OsteoGen®)

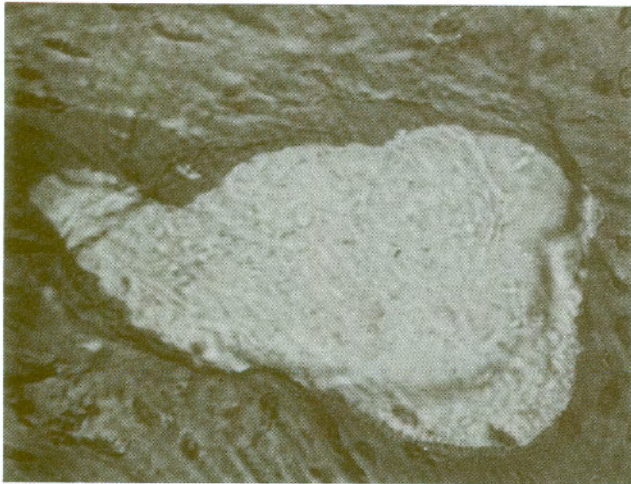


Figure 15. Osteoblasts (A) at interface with resorbing hydroxylapatite crystalline particle (B) (200 x).

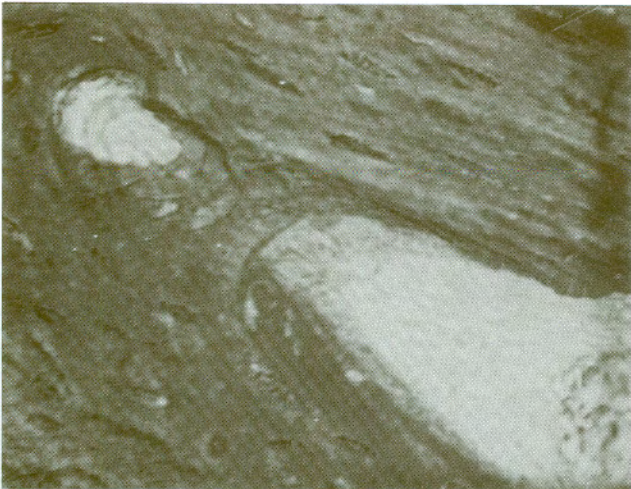


Figure 16. Resorbable hydroxylapatite particle showing erosion of surface. These particles appear to be largely intact, as opposed to those seen in Figs. 4-16. This highly suggests a time-dependent resorption process, since the preceding graft had been implanted for 14 months, while in this case the histological study was done after only four months (200 x).

particles show surface erosion illustrating the resorption process (Figs. 15, 16).

### Discussion

In over 450 applications, this author has exclusively used resorbable hydroxylapatite (OsteoGen®) for the repair of severe osseous defects, cysts, craters, apicoectomies, sinus elevation augmentations, and in conjunction with all of his other routine endosseous implant surgical cases. Resorbable hydroxylapatite can be used in place of

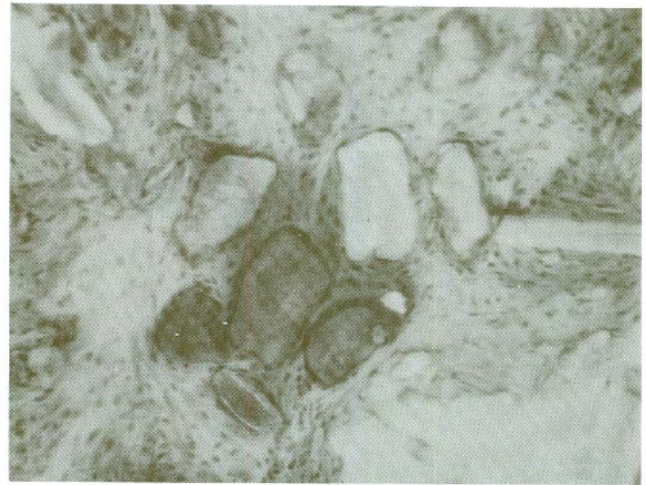


Figure 17. A bone core specimen taken by the author of another case after 14 months' implantation in the crypt of an impacted 3rd molar that was grafted with resorbable hydroxylapatite. Note smaller particle size of refractile HA crystals and the change of color of the newly formed bone from red fuchsin stain to yellow, indicating increased mineralization. Brown areas indicate high-density areas resistant to the fuchsin stain absorption (100 x).

autogenous or freeze-dried bone grafts with very predictable results.

The grafting coagulum has been utilized successfully with submersible and non-submersible types of implants. In most cases, the grafts were placed in medullary applications to promote the regeneration of cancellous bone. In the alveolar ridge repair reported in this paper, a fairly large area of missing cortical bone was replaced by the regeneration of lamellar bone, with evidence of a Haversian system typical of cortical bone.

### Conclusion

OsteoGen® is a highly micro-porous, non-sintered (non-ceramic), bioactive bone grafting material with a predictable, controlled resorption rate. As the material resorbs, it acts as a mineral reservoir and predictably induces new bone formation *via* osteoconductive mechanisms. The material appears to be very biocompatible in both hard and soft tissues. When placed in direct contact with bone, there is little if any intervening soft tissue. OsteoGen® (H.A. Resorb)™ provides a key raw material which the body naturally uses to create bone. Further, the crystalline structure of the resorbable hydroxylapatite (RHA) enhances its chemical composition by serving as a scaffold upon which the body can build new bone as it slowly resorbs the material. Comparison of the histology of the bone core specimens taken by this author supports the "mineral reservoir" hypothesis (Fig. 17).

---

## References

- CRANIN, A.N.; TOBIN, G.P.; and GELBMAN, J. (1987): Applications of Hydroxylapatite in Oral and Maxillofacial Surgery, Part II: Ridge Augmentation & Repair of Major Oral Defects, *Compend Contin Ed Dent* 8: 334-345.
- FINN, R.A.; BELL, W.H.; and BRAMMER, J.A. (1980): Interpositional Grafting with Autogenous Bone and Corraline Hydroxylapatite, *J Max Fac Surg* 8:217-220.
- HUBBARD, W. (1974): *Physiological Calcium Phosphate as Orthopedic Implant Material*, PhD Thesis, Marquette University.
- JARCHO, M.; KAY, J.F.; DROBECK, H.P.; and DOREMUS, R.H. (1976): Hydroxylapatite Interface, *J Bioeng* 1: 79-92.
- JUDY, K. (1986a): Lecture, American Academy of Implant Prosthodontics, Annual Meeting, Las Vegas, NV (March 7-8).
- JUDY, K. (1986b): Oral Implantology Case Reports, *NY State Dent J* 52: 24-26.
- LEMONS, J.E. (1985): Quantitative Characterization and Performance of Porous Implants for Hard Tissue Applications, ASTM STP 859, Philadelphia.
- LeGEROS, R.Z. (1988): Calcium Phosphate Materials in Restorative Dentistry: A Review, *Adv Dent Res* 2: 164-180.
- LINKOW, L. (1984): Bone Transplants Using the Symphysis, the Iliac Crest and Synthetic Bone Materials, *J Oral Implantol* 11:211-217.
- LINKOW, L. (1986): Lecture, 1st Annual U.S. Linkow Congress, Leawood, KS (June 20-21).
- McKINNEY, R.V., Jr. and LEMONS, J.E. (1985): **The Dental Implant, Clinical and Biological Response of Oral Tissues**, Littleton, MA: PSG.

---

Correspondence should be addressed to 7100 Plantation Road, Suite 9, Pensacola, Florida 32504.